REVIEW

Practical Management of Progressive Multifocal Leukoencephalopathy and Immune Reconstitution Inflammatory Syndrome

Guillaume Martin-Blondel,[1,2,3] Busranur Agac,[4] and Irene Cortese[4]

Neurol Clin Pract. 2026;16:e200594. doi:10.1212/CPJ.0000000000200594

Correspondence
Prof. Martin-Blondel
martin-blondel.g@chu-toulouse.fr

Abstract

Purpose of Review

The aim of this narrative review was to provide treating physicians with practical guidance on the management of progressive multifocal leukoencephalopathy (PML), offering a rational, evidence-informed approach to diagnosis and treatment based on published literature and the authors' collective clinical experience.

Recent Findings

The management of PML requires precise characterization of disease status at presentation and throughout follow-up. We begin by outlining the clinical scenarios in which PML should be suspected, emphasizing that disease presentation is shaped by the strength and quality of the host's antiviral immune response. We then detail the evaluation of patients at the time of diagnosis and during follow-up, with particular attention to defining whether PML is presenting in its classic form, with inflammatory features, or in the context of immune reconstitution inflammatory syndrome. This assessment should incorporate prognostic markers to evaluate the potential for immune recovery and virologic control. We further summarize the current standard of care and identify clinical contexts in which experimental immunotherapeutic interventions to facilitate restoration of JC virus–specific immune functions may be considered, emphasizing the importance of individualized, risk-benefit–based decision making. Notably, such experimental immunotherapies are likely unnecessary and may even be harmful, once immune reconstitution has already been achieved and virologic control is evident. Finally, we address the management of inflammation in PML, underscoring that not all inflammatory presentations warrant corticosteroid therapy.

Summary

The management of PML remains a significant clinical challenge. Standardizing assessment protocols across centers may enhance data quality and comparability and facilitate future collaborative and data-sharing efforts.

Introduction

Progressive multifocal leukoencephalopathy (PML) can result from JC polyomavirus (JCV) infection in immunocompromised individuals.[1] The single effective therapeutic strategy remains the reconstitution of host antiviral immune responses. Experimental immunotherapy, which aims to accelerate immune recovery of JCV-specific immune functions, is an evolving field with promising approaches that need further validation. On the contrary, corticosteroids may be required to control an excessive inflammatory response in the setting of immune reconstitution inflammatory syndrome (IRIS); however, the lack of clear guidance for appropriate use of steroids leads to gross variability in timing and dosing, with potential detrimental outcomes. Controlled clinical trials are very challenging in the field of orphan

[1]Department of Infectious and Tropical Diseases, Toulouse University Hospital, France; [2]Toulouse Institute for Infectious and Inflammatory Diseases, INSERM UMR1291–CNRS UMR5051, Toulouse III University, France; [3]NEO-I3D Research Group, Toulouse University Hospital, France; and [4]Experimental Immunotherapeutics Unit, National Institute of Neurological Disorders and Stroke, Bethesda, MD.

Copyright © 2026 American Academy of Neurology

Copyright © 2026 American Academy of Neurology. Unauthorized reproduction of this article is prohibited.

Downloaded from https://www.neurology.org by Cardiff University (cfu) / Wales on 11 February 2026

diseases such that, most often, we must rely on observational studies, inherently limited by their retrospective nature, heterogeneous definitions, incomplete understanding of disease pathogenesis, and inconsistent follow-up. The aim of this narrative review was to provide guidance for treating physicians by proposing a rational approach to workup and treatment based on existing evidence and the authors' collective experience. Harmonizing such approaches presents the opportunity to improve the quality and comparability of data collected across centers, with the objective of facilitating future data-sharing efforts.

When Should PML Be Suspected?

Although the 2013 American Academy of Neurology consensus criteria provided alternative paths to PML diagnosis, this is often not straightforward.[2] The patient's underlying condition and previous treatment exposures significantly affect the risk of developing PML. Therefore, known immune dysregulation should prompt consideration of PML in a patient with progressive neurologic symptoms. Leading causes include, in order of prevalence, HIV/AIDS, hematologic malignancies (HM), immune-mediated diseases (IMD), cancer, solid organ transplantation (SOT), and primary immune deficiencies (PID).[3,4] While the incidence of HIV-associated PML has decreased over the past decades because of advancements in antiretroviral treatment (ART),[4,5] the incidence of iatrogenic PML associated with the use of immunomodulatory monoclonal antibodies has increased.[4,6,7] These include agents targeting CD20, CD30, CD52, B-cell activating factor (BAFF), CD11a, and, most notably, α4β1-integrin.[8,9] The expanding indications, availability, and use of targeted therapies, including tyrosine kinase inhibitors[10] and chimeric antigen receptor T-cell therapies,[11,12] may further broaden the population at risk. In addition, certain immune-mediated diseases such as sarcoidosis may increase the risk of PML independently of immunosuppressive medication use.[13] No validated biomarkers or effective risk mitigation strategies are currently available except in the specific case of natalizumab-treated patients where the anti-JCV antibody index enables risk stratification.[8] Studies show that lymphopenia is a common risk factor of PML development in patients with multiple sclerosis (MS) treated with dimethyl fumarate and vigilant, consistent monitoring of absolute lymphocyte count over the course of treatment can be an effective method of early identification of patients at risk.[14] However, PML can emerge under less typical circumstances that may not immediately prompt physicians to consider this diagnosis. First, immunosuppression might be occult at the onset of neurologic symptoms, with PML being the initial manifestation of immune dysregulation. Second, PML can occur in conditions not considered to be primarily immunosuppressive, such as chronic kidney disease or cirrhosis.[15]

Clinical presentation in PML is shaped by the strength of the host antiviral immune response (Figure 1). The classic lack of inflammation on imaging can be replaced by varying degrees of contrast enhancement in the context of less profound immunosuppression (e.g., natalizumab-associated PML).[16] Such presentations are often referred to as "inflammatory PML" and may be associated with better prognosis.[17] It is important to note that PML can go unnoticed only to be unmasked with development of overt inflammatory features during immune recovery, such as in patients who recently initiated ART for HIV infection or those who recently discontinued or tapered immunosuppressive drugs. In these situations, clinical context is paramount for identification of IRIS.[18] In addition, JCV CNS infection can manifest with atypical phenotypes, including progressive cerebellar atrophy (granule cell neuronopathy [GCN]),[19] meningitis,[20] or encephalopathy (related to infection of cortical pyramidal neurons),[21] suggesting that the spectrum of JCV-related disease may be broader than currently recognized. In this context, ocular tap in 2 immunocompromised patients—one presenting with macular changes and the other with retinopathy[22,23]—revealed persistent detection of JCV DNA by PCR. In the latter, JCV-related retinopathy was confirmed by retinal biopsy.[23] These findings suggest a greater pleomorphism than previously appreciated, opening the possibility that additional rare presentations might be identified in the future. Finally, JCV DNA may not be detected in CSF if an insufficiently sensitive assay is used or early in disease when viral burden is low. To this end, the treating physician must be aware of the sensitivity of the JCV DNA PCR assay, and, if appropriate, opt for retesting using a highly sensitive PCR assay (limit of detection <50 copies/mL). However, even when a high-sensitivity PCR assay is used, JCV DNA load in the CSF may not correlate with lesion volumes.[24] Consequently, a negative JCV PCR in CSF result does not rule out PML.[25] In such cases, repeat testing or brain biopsy is needed.

Therefore, progressive neurologic symptoms developing in immunocompromised patients should prompt clinicians to consider JCV infection, even if some clinical or imaging features are atypical.

How to Evaluate a Patient With a New Diagnosis of PML?

A multiparametric assessment is essential to guide the physician in managing patients. The patient's medical history should be reviewed to identify immune compromise. Familial medical history may reveal patterns indicative of inborn error of immunity. In patients receiving immunosuppressive drugs, the specific type, duration, and dosing, as well as tapering or interruption, should be determined.

Downloaded from https://www.neurology.org by Cardiff University (cfu) / Wales on 11 February 2026

Copyright © 2026 American Academy of Neurology. Unauthorized reproduction of this article is prohibited.

Figure 1 Clinical Presentation in PML Is Shaped by the Strength of the Antiviral Immune Response

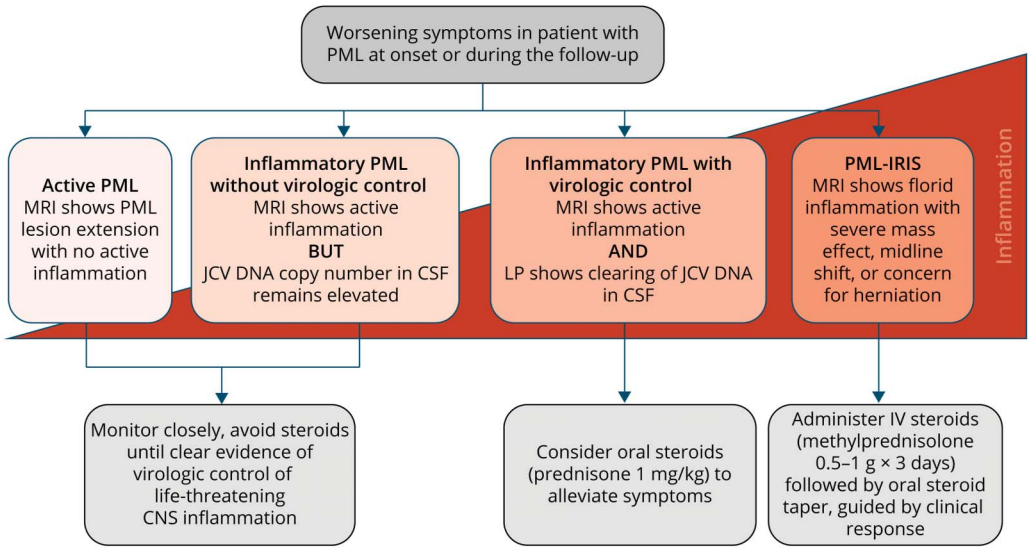

Active PML has historically been characterized by the absence of inflammation on imaging. However, brain MRI may reveal varying degrees of contrast enhancement, particularly in cases of less profound immunosuppression, or when PML is unmasked during immune recovery, leading to overt inflammatory features. Accurately determining where a patient falls along this inflammatory spectrum is essential because therapeutic strategies differ substantially depending on the underlying immune context. Management of inflammation in PML relies on the measured use of corticosteroids, but not all inflammation in PML requires treatment. PML = progressive multifocal leukoencephalopathy.

For both patients with and without known conditions predisposing to PML, laboratory workup should at a minimum include CD4 and CD8 T-cell, B-cell, and natural killer (NK) cell enumeration; immunoglobulin quantification; and HIV testing. A body CT scan and/or PET scan may be helpful for detecting occult cancer, hematologic malignancy, or sarcoidosis or for assessing the status of known neoplasm. Depending on clinical context, additional investigations for patients with no known underlying condition may be needed and should be performed under direction of specialists.

Brain MRI with gadolinium contrast, including at least T1-weighted and T2-weighted sequences, and diffusion-weighted imaging (DWI) should be performed to monitor extension and distribution of PML lesion burden over time.[26] In the setting of GCN, demyelinating lesions might be lacking and global cerebellar atrophy may be the only imaging finding.[19] Quantitative JCV DNA in the CSF can provide a measure of virologic control over time and of response to treatment.[27] While, at present, quantification of JCV DNA in the urine and JCV serology have no established diagnostic value for confirming PML, investigation of potential negative predictive value of negative serology would be of interest.

The objectives of this initial evaluation were to (1) ascertain the underlying condition associated with PML risk; (2) define whether the PML has classic or inflammatory features, or whether clinical onset occurred in the context of IRIS; (3) estimate the ability of the patient's antiviral immune responses to recover; and (4) determine whether the patient would benefit from immunotherapeutic intervention to facilitate restoration of JCV-specific immune functions in addition to standard of care (SOC).

What Is the SOC in PML?

Rapid restoration of anti–JCV-specific immune function is the only approach currently available to control JC viral replication and stabilize PML, as there is no validated antiviral agent available for the treatment of JCV infection.

In the context of HIV infection, this strategy involves the early initiation of ART to enable rapid control of HIV replication and subsequent immune restoration (Figure 2).[28] This has been best illustrated by the improved prognosis of HIV-related PML in the ART era.[28] In further support, a five-drug ART regimen including enfuvirtide, given early after PML diagnosis, was suggested to improve the one-year cumulative probability of survival compared with HIV-infected patients placed on conventional triple-drug ART after PML diagnosis.[29] First-line recommended combinations including integrase strand transfer inhibitors (INSTIs) should be prioritized because of their high virologic potency against HIV replication.[30] It is important to note that ART initiation with INSTI results in greater CD4/CD8 ratio recovery over time compared with non-nucleoside reverse transcriptase inhibitor (NNRTI)–based or protease inhibitor–based ART[31] and is associated with lower mortality at 3 years among patients with advanced HIV disease.[32] Although long-term clinical effects are not yet proven in people living with HIV,

Downloaded from https://www.neurology.org by Cardiff University (cfu) / Wales on 11 February 2026

Copyright © 2026 American Academy of Neurology. Unauthorized reproduction of this article is prohibited.

Figure 2 Management of PML

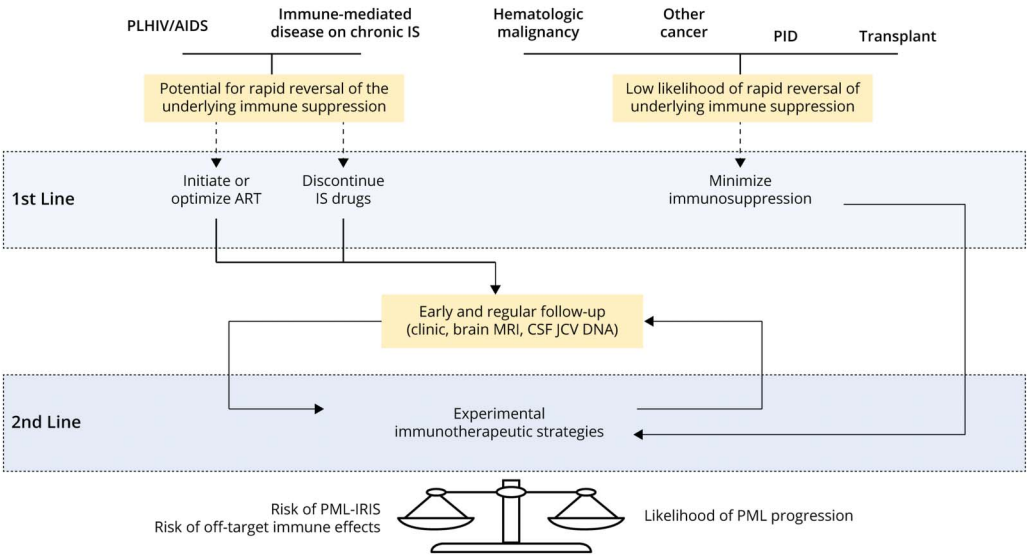

The management of PML can be complex and often requires a multidisciplinary approach, potentially involving infectious disease specialists, neurologists, neuroradiologists, virologists, immunologists, specialists in the underlying condition, and rehabilitation professionals. Prompt restoration of anti–JCV-specific immune function remains the cornerstone of treatment and the only proven strategy to stabilize disease progression and control viral replication. Experimental immunotherapeutic approaches aimed at enhancing antiviral immune restoration may be considered on a case-by-case basis, taking into account the underlying disease and clinical trajectory. However, such interventions should be avoided in patients who have already achieved effective immune reconstitution and virologic control. IS = immunosuppressive drug; PID = primary immune deficiencies; PML = progressive multifocal leukoencephalopathy.

these immunologic benefits, driven by the effects on both CD4 and CD8 cell dynamics, might improve control of JCV replication and PML outcomes. Contrary to some other opportunistic CNS infections (ie, tuberculosis), in case of PML, ART should be initiated without delay.

In the context of iatrogenic PML, the SOC involves discontinuing immunosuppressive agents or rapidly tapering dose if they cannot be completely stopped. This holds significant risk in some clinical settings, such as solid organ transplant recipients with potentially life-threatening graft loss or immune-mediated diseases involving vital organs. In patients who require ongoing immunosuppression, the optimal reduction in the net state of immune suppression, the appropriate duration of immunosuppression tapering, and potential alternative immunosuppressive strategies all remain areas of uncertainty. For PML associated with natalizumab-treated MS, plasma exchange or immunoadsorption strategies aimed at accelerating antibody clearance have been used, with no evidence of benefit on survival.[33] The efficacy of plasma exchange for cell-depleting monoclonal antibodies has not been established.

Apart from these considerations, managing a patient with PML requires general medical care to anticipate and address common complications. Electrolyte balance should be optimized, because factors such as hyponatremia or dehydration can worsen the patient's neurologic status. Seizures should be promptly identified and managed, especially in cases of acute clinical worsening. Disability necessitates prevention of complications related to immobility, such as deep vein thrombosis or decubitus ulcers. Rapidly worsening dysphagia carries a high risk of malnutrition and aspiration pneumonitis and should be addressed early through swallow evaluation and parenteral or enteral feeding. Rehabilitation therapists should be involved early, including physical, occupational, speech, and low-vision specialists. Appropriate psychological support for both the patient and their family is essential. Finally, given the high likelihood of rapid and relentless clinical deterioration, discussions about goals of care should be addressed early and revisited periodically over the course of disease with the patient, the multidisciplinary medical team, and, as appropriate, their family.

How to Interpret Inflammatory Features in PML?

Inflammation driven by restoration of the antiviral immune response occurs as a continuum, ranging from absence in the setting of classic PML to florid in the setting of PML-IRIS (Figure 3). It is essential for physicians to gauge where a patient lies on this spectrum, as treatment strategies differ drastically.

Classic PML typically occurs in severely immunocompromised patients who lack any effective antiviral immune activity. In this setting, brain MRI does not demonstrate contrast enhancement—a biomarker of blood-brain barrier breakdown associated with active inflammation—and pathology, when performed, may show minimal inconsistent, predominantly perivascular T-cell infiltration.[34] It is

Downloaded from https://www.neurology.org by Cardiff University (cfu) / Wales on 11 February 2026

Copyright © 2026 American Academy of Neurology. Unauthorized reproduction of this article is prohibited.

Figure 3 Inflammatory Continuum Over the PML Disease Course

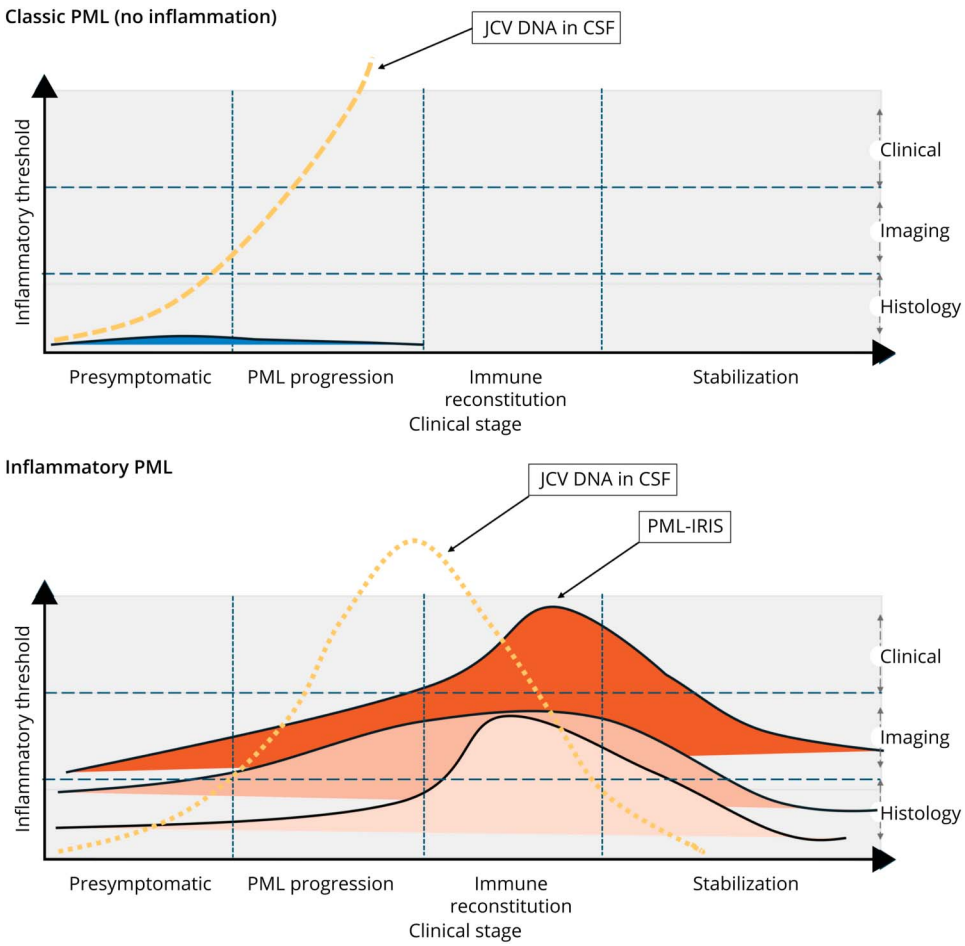

Inflammation resulting from the restoration of antiviral immune responses occurs along a continuum—from absent in classic PML to pronounced in PML-IRIS. Classic PML typically arises in severely immunocompromised patients who lack effective antiviral immunity. In such cases, brain MRI typically shows no contrast enhancement, and when available, neuropathologic examination reveals minimal or inconsistent perivascular T-cell infiltration. CSF JCV DNA levels are usually high and may continue to rise. Here, CNS injury is primarily driven by uncontrolled lytic infection of oligodendrocytes, and treatment should focus on restoring immune function to achieve virologic control. When antiviral immune responses are present—either at disease onset or emerging during follow-up—varying degrees of inflammation may develop. This may manifest as T-cell infiltration within the parenchyma; contrast enhancement on brain MRI; and, in some cases, clinical worsening. The latter defines PML-IRIS and reflects an exaggerated immune response against JCV-infected cells. IRIS = immune reconstitution inflammatory syndrome; JCV = JC polyomavirus; PML = progressive multifocal leukoencephalopathy.

increasingly recognized that subtle or punctate enhancement is not uncommon at first presentation of PML, as described in untreated HIV infection[17] and in natalizumab-associated PML,[16] but this alone cannot be considered indicative of a viable antiviral immune response. In these scenarios, CNS injury is likely still predominantly mediated by the lytic infection of oligodendrocytes, leading to centrifugal demyelination with associated axonal loss and progressive clinical worsening. Treatment strategies should focus on restoration of the immune system to regain virologic control.

At the other end of the spectrum lies PML-IRIS, characterized by florid CNS inflammation. PML-IRIS has been reported in 16.7% of HIV-related PML cases at some point during disease course[35] and in almost all natalizumab-related PML cases after treatment discontinuation.[16] It is important to note that this can also be the first manifestation of PML, which has been referred to as PML unmasking.[36] IRIS results from an excessive and possibly dysregulated immune response against pathogen-derived antigens.[18] While this leads to improved control of JCV replication, it comes at the cost of inflammatory injury, clinical worsening related to mass effect, and likely an excess of bystander glial and neuronal loss.[37] Without a specific biomarker or consensus definition across PML patient populations, diagnosis of PML-IRIS is commonly based on imaging or is presumed based on clinical setting.[38] As such, overtreating or undertreating inflammation in PML is not uncommon. As a rule-of-thumb, treatment of inflammation in PML should be undertaken judiciously and reserved for cases of severe CNS inflammation. When lumbar puncture can be performed, clear evidence of virologic control may lend support to this therapeutic decision. Pitfalls in recognizing PML-IRIS can arise from the physician's failure to identify the temporal relationship between PML occurrence and the onset of immune recovery. Similarly, noncontrast brain MRI may preclude accurate assessment of CNS inflammation. Conversely, onset of contrast-enhancing lesions on a follow-up brain MRI in known PML with no clinical worsening should be considered a physiologic response to infection that does not require treatment. Corticosteroids should not be administered preemptively because they may impair ability to control infection.

While extremes may be more easily identified, it is otherwise not always straightforward to understand whether symptom

Downloaded from https://www.neurology.org by Cardiff University (cfu) / Wales on 11 February 2026

Copyright © 2026 American Academy of Neurology. Unauthorized reproduction of this article is prohibited.

worsening is related to PML progression or to mounting inflammation without longitudinal assessments. Careful monitoring before and after any treatment intervention is, therefore, key for guiding next steps, including both imaging and JCV viral load measurement in CSF.

Are There Any Clinically Relevant Prognostic Markers?

PML is a devastating disease, with one-year mortality ranging from 20% to 90%.[39,40] Many factors contribute to PML prognosis, and recognizing these is important to identify patients at the highest risk of poor outcomes. For these, potential benefits of experimental immunotherapy aimed at enhancing antiviral immune restoration may outweigh the risks of immune-mediated complications (Table 1).

The primary prognostic factor is the underlying condition, reflecting the severity of immune deficiency and the likelihood of the patient's immune system to recover. In a cohort of 584 patients with incident PML, with a one-year all-cause mortality rate of 38.2% (34.2–42.2), mortality was 17% and 33% in patients with iatrogenic PML related to immune-mediated diseases (mostly represented by MS) and HIV-related PML, respectively.[3] In these cases, stopping immunosuppressive drugs or initiating ART can often promptly reverse immunosuppression. Conversely, mortality varied from 42% to 68% in patients with solid organ transplant, primary immune deficiency, hematologic malignancy, and solid cancer—conditions associated with severe immune deficiency and a lower likelihood of timely immune response recovery.

Similarly, factors associated with improved survival include age at PML diagnosis,[3,25] higher performance status at baseline,[41] shorter delay to PML diagnosis,[41] less severe motor weakness,[25] and less profound CD4 T-cell lymphopenia.[42] Virologic and radiographic biomarkers associated with improved survival include measurable JCV-specific T-cell responses early in the course of PML,[43] lower JCV copy number in CSF at baseline,[4,29] JCV clearance from CSF during follow-up,[25,27] and reduced MRI disease burden during follow-up.[25] In this regard, we have shown that a defined decline in quantitative JCV DNA in CSF—possibly as small as $0.25\log_{10}$—has the potential to serve as a valuable biomarker of PML disease course and treatment response.[27] All these biomarkers hold promise as direct or indirect measures of severity of immunosuppression and of its potential reversal.

Finally, functional evaluation of the immune response against JCV, assessing cytokine production or cell proliferation after stimulation with JCV major antigens, may reflect the ability of the patient's immune system to control JCV replication; however, none of these assays have been standardized, and at present, their availability is limited to the research setting. Although a correlation between presence of antiviral immune response and survival is described,[28,43,44] the relevance of these assays to help manage patients with PML still has to be investigated.

When Might Experimental Immunotherapeutic Interventions Be a Reasonable Treatment Option?

Emerging immunotherapeutic strategies aimed at promoting the restoration of antiviral immune responses have garnered increasing attention. These strategies mainly include the use of interleukin-7 (IL-7)[45] and immune checkpoint inhibitors (ICIs).[46,47] A third approach is the adoptive transfer of polyomavirus-specific T cells from a related or unrelated donor.[41,48-50] While these strategies are promising, it is important to emphasize that they remain experimental, with incomplete understanding of risks or of which patients have the greatest likelihood of benefit.

Although based on scientific rationale, these strategies are only supported by a low level of evidence, primarily case series and literature reviews involving heterogeneous populations of patients with PML referred to tertiary care centers; despite reported benefit, mortality remains high (Table 2). Because all patients also received SOC in the form of discontinuing immunosuppressive medications or starting ART, as applicable to the underlying disease, the direct impact of immunotherapies on survival is difficult to ascertain in noncontrolled studies. Furthermore, the risk-to-benefit ratio of such strategies is not fully understood, with various ranges of adverse events reported, likely dependent on the

Table 1 Key Prognostic Factors for Outcomes in PML

More favorable	Less favorable
ART-treated HIV or MS-related PML Measurable JCV-specific immune responses Lower CSF JCV DNA at baseline CSF JCV DNA clearance during follow-up CD4 T-cell count >100/mL	PML related to hematologic malignancy, cancer, solid organ transplant, primary immune deficiency High initial CSF JCV load Increase in JCV DNA in the CSF Male sex and age >60

Abbreviations: ART = antiretroviral treatment; JCV = JC polyomavirus; PML = progressive multifocal leukoencephalopathy.

Downloaded from https://www.neurology.org by Cardiff University (cfu) / Wales on 11 February 2026

Copyright © 2026 American Academy of Neurology. Unauthorized reproduction of this article is prohibited.

Table 2 Summary of Studies Using Immunotherapy for Treatment of PML[a]

	Study	Design	Number of patients	One-year survival (%)	IRIS (%)	Adverse events (not including IRIS) (%)
rhIL-7	Lajaunie et al.[46]	Multicentric retrospective survey	64 • HIV: 27 • HM: 16 • PID: 13 • SOT: 4 • IMD: 4	35/64 (54.7) • HIV: 14/27 (51.9) • HM: 8/16 (50) • PID: 7/13 (53.9) • SOT: 3/4 • CID: 3/4	5/64 (7.8)	15/64 (23.4), 8/15 being local reactions and flu-like symptoms
Checkpoint inhibitors	Boumaza et al.[47]	Multicentric retrospective survey	79 • HIV: 12 • HM: 38 • PID: 14 • SOT: 2 • IMD: 8 • Cancer: 5	41/79 (51.9) • HIV: 6/12 (50) • HM: 19/38 (50) • PID: 8/14 (57.1) • SOT: 0/2 • CID: 5/8 (62.5) • Cancer: 3/5 (60)	15/79 (19)	24/79 (30.4), 14/24 being potential off-target adverse events
Polyomavirus-specific T cells	Cortese et al.[50]	Monocentric prospective cohort	12 • HM: 6 • PID: 3 • IMD: 2 • Other: 1[b]	7/12 (58.3) • HM: 4/6 (66) • PID: 0/3 • CID: 2/2 • Other: 1	None	No infusion reactions No grade 3 or 4 adverse event related to the treatment 1 neutropenia case, 1 fever episode and 1 pruritis case were deemed possibly related
	Pocora et al.[42]	Monocentric prospective cohort	19 • HM: 12 • PID: 5 • IMD: 2	6/19 (31.6) • HM: 4/12 (33) • PID: 2/5 (40) • CID: 0	1/19 (5.3)	Not reported
	Mohn et al.[51]	Multicentric retrospective survey	28 • HIV: 2 • HM: 17 • PID: 4 • IMD: 4 • Other: 1[b]	20/28 (71.4) vHIV: 2/2 • HM: 11/17 (64.7) • PID: 3/4 • CID: 4/4 • Other: 0	3/28 (10.7)	Transient skin rash in 3 patients Increase in liver enzymes in 1 patient

Abbreviations: IMD = immune-mediated disease; HM = hematologic malignancy; IRIS = immune reconstitution inflammatory syndrome; PIDs = primary immune deficiencies; PML = progressive multifocal leukoencephalopathy; SOT = solid organ transplant recipient.
[a] Excluding studies with fewer than 5 patients.
[b] Hepatitis B and D and chronic kidney disease with hemodialysis.

underlying condition. Translational studies and clinical trials are thus necessary to validate their effectiveness and safety.

These immunotherapeutic strategies may be valid options for select patients unlikely to achieve timely immune recovery, guided by personalized decision making that considers likelihood of immune recovery and the risk of immune-mediated adverse effects (Figure 2). For patients with long-standing immune deficiency resulting as sequela of cancer treatments, those with primary immune deficiencies, or transplant recipients—conditions associated with the worst PML prognosis—an immunotherapeutic strategy might be considered along with minimization of any active immunosuppression, where possible. Conversely, for patients with potential for rapid reversal of immunosuppression, such as those with HIV infection and iatrogenic PML-associated short-acting, non–cell-depleting therapies, SOC alone should be applied first line, with experimental immunotherapeutic strategies considered early upon failure during follow-up. Immunotherapeutic strategies are to be avoided in the setting of PML-IRIS, because they could precipitate life-threatening CNS inflammation and would not be expected to provide incremental benefit.

When an experimental immunotherapy is indicated, the choice should be pragmatic and personalized because, at present, good evidence or predictive markers of efficacy are lacking. Each of the 3 main strategies has advantages and drawbacks. IL-7 and adoptive transfer of T cells may be particularly suited for severely lymphopenic patients, because the benefit of blocking checkpoint molecules in this context is less likely to be successful. ICIs might be preferred if the underlying condition itself could also benefit from immune checkpoint blockade, such as Hodgkin lymphoma or certain solid cancers, effectively using one treatment to address multiple issues. The use of ICIs holds greater risk in patients with immune-mediated diseases and hematopoietic stem cell transplant recipients in whom exacerbation of flares of the underlying condition or graft-versus-host disease could lead to significant morbidity and necessitate resumed immunosuppression.[51,52] However, broader use of ICIs will help clarify specific risks in patients with underlying immune-mediated diseases. For example, recent data suggest that the overall risk of MS reactivation under ICIs is low and likely related to discontinuation of disease-modifying therapy after a cancer diagnosis.[53] The therapeutic index of ICIs in solid organ transplant recipients is also limited by the risk of transplant rejection.[54] In these situations, adoptive transfer of T cells may be preferred. ICI use in HIV-related PML is limited to only a few cases to date, with most of these having

Downloaded from https://www.neurology.org by Cardiff University (cfu) / Wales on 11 February 2026

Copyright © 2026 American Academy of Neurology. Unauthorized reproduction of this article is prohibited.

a favorable outcome. The risk of promoting IRIS is a major concern in this patient group and underscores the importance of patient selection and monitoring.[55] There is far less experience using IL7; however, at least theoretically, the adverse effect profile could be similar to that of ICIs. Finally, the accessibility of these strategies is limited by costs, complexity, and availability. IL7 is not commercially available and, therefore, only provided in the clinical research setting or directly by the manufacturer on compassionate use basis. While ICIs are readily available for prescription, adoptive T-cell therapy may be limited by the need to identify a suitable donor—both compatible with the recipient and possessing robust anti-JCV activity. This process is time-consuming and may be incompatible with the urgency of the clinical situation, representing a major barrier to the timely implementation of this therapeutic approach. Third-party cell banks have overcome some of these issues but are available only in a few centers worldwide.

Whenever possible, experimental therapies should be administered as part of a clinical study to ensure rigorous evaluation of their efficacy and safety.

How Do We Monitor Patients During Follow-Up?

Monitoring a patient with PML must be tailored to the individual's clinical context, guided by therapeutic decisions, and may require repeated multiparametric assessments to optimize management. In our practice, we usually conduct monthly follow-up during the initial 6 months of PML management or until patient stabilization is achieved or CSF JCV DNA is persistently undetected. This period coincides with the greatest PML-related mortality.[3] Clinical follow-up monitors for change in neurologic examination and any intercurrent medical complications, as well as addresses psychological distress in the patient and their family. Brain MRI with contrast is repeated at each visit, as is blood work to track absolute lymphocyte counts. It is important to note that quantitative CSF JC viral load provides a measure of direct virologic control, as its decline—or lack thereof—is a predictive biomarker.[25,27] In our practice, we consider changes greater than 0.5 $\log_{10}$ to be clinically relevant, while 2 JCV DNA measurements with changes less than 0.5 $\log_{10}$ may be an early sign of stabilization. In the event of neurologic deterioration, brain MRI patterns and JCV DNA in CSF can help differentiate between PML progression and development of CNS inflammation (Figure 3), avoiding need for definitive demonstration by histopathology.

In patients who survive PML beyond 9–12 months, the frequency of monitoring can be reduced and the need for repeat brain MRI and/or lumbar puncture can be driven by the clinical course. At this stage, follow-up will primarily focus on clinical assessments and rehabilitation, with brain MRI only pursued in the event of neurologic worsening. Lumbar puncture is not medically useful at this stage. Most of the patients will have neurologic sequela, and often, these are severe and irreversible.[56] Regular follow-up with the specialist managing the underlying condition remains essential, especially considering many patients may have to forgo optimal management of the predisposing disease to maintain PML control. Notably, clinicians should be aware that discontinuation of certain medications is more likely to be associated with relapse of the underlying disease; for example, discontinuation of sphingosine-1-phosphate receptor modulators is associated with a high likelihood of MS relapse, even compared with discontinuation of natalizumab.[57]

Conversely, the frequency of PML relapses after initial survival is unknown, but most are seen with worsened immunosuppression due to uncontrolled HIV infection in the setting of noncompliance or drug resistance, or due to reintroduction of immunosuppressive drugs to manage progression of the underlying condition. Thus, resuming immunosuppressive therapy in a patient with a history of PML requires careful consideration and multidisciplinary management, including weighing the risk-benefit ratio and selecting immunosuppressive agents with the lowest risk of JCV reactivation and greatest possibility of rapid reversal. With increasing numbers of patients with underlying immune-mediated disease surviving PML, there may be opportunity to explore optimal strategies. If immunosuppressive therapy is resumed, a monitoring plan including clinical and MRI evaluations and CSF JCV DNA measurements should be established at baseline and conducted regularly.

How Do We Treat Inflammation in PML?

Understanding the significance of occurrence of inflammation in PML is crucial for clinicians managing immunocompromised patients because recognition and appropriate management can affect outcomes. Not all inflammation in PML requires treatment, and corticosteroids should not be used to treat isolated radiologic evidence of inflammation in the absence of clinical deterioration, as this should be interpreted as physiologic and beneficial antiviral immune responses that should be preserved (Figure 1). When treatment is indicated, steroids are the mainstay; however, dose, route of administration, and duration of treatment vary widely in the literature.[58,59] While corticosteroids are commonly given, the authors would advocate judicious utilization. Indeed, high-dose steroids have a profound impact on the JCV-specific T-cell response and can compromise control of JCV replication.[60] Moreover, most cases of inflammatory PML are characterized by mild symptoms and limited CNS inflammation that are well tolerated. In our experience, a starting dose of 1 mg/kg of prednisone can be proposed with tapering over several weeks (for instance, of 10 mg/wk). Higher doses, up to 0.5–1 g/d in bolus, may be justified in the short-term life-

Downloaded from https://www.neurology.org by Cardiff University (cfu) / Wales on 11 February 2026

Copyright © 2026 American Academy of Neurology. Unauthorized reproduction of this article is prohibited.

TAKE-HOME POINTS

- The management of progressive multifocal leukoencephalopathy (PML) can be complex and often requires a multidisciplinary approach, potentially involving—depending on the patient and the treating physician's expertise—infectious disease specialists, virologists, neurologists, neuroradiologists, immunologists, hematologists, and other specialists in the underlying condition, as well as rehabilitation teams.
- First-line management for PML is directed at reversing the immune suppressed state by early initiation of effective antiretroviral therapy in people living with HIV or discontinuation or tapering of immunosuppressive drugs in the context of iatrogenic PML. Beyond these clinical scenarios, however, a clear standard of care is lacking.
- Experimental immunotherapeutic strategies to facilitate restoration of JC virus–specific immune functions may be considered on a case-by-case basis, depending on the type of underlying condition and clinical course, and should be avoided in the setting of effective immune reconstitution achieving virologic control.
- Management of inflammation in PML relies on the judicious use of corticosteroids. Not all inflammation in PML requires treatment.

threatening cases (e.g., brain herniation due to mass effect). Corticosteroid dependence, with new worsening when the dose of steroids is tapered, can occur and necessitates close clinical monitoring. The optimum dose and duration of steroids remain to be established.

Conclusion

The management of PML remains a clinical challenge that requires precise characterization of disease status at presentation and rapid initiation of SOC. Current assessment relies on an integrated interpretation of clinical findings, MRI, and virologic parameters. Emerging assays evaluating antiviral immune responses and their kinetics may soon offer additional, clinically relevant dimension to disease monitoring. When an experimental immunotherapy is considered as an adjunct to standard care, the decision must be carefully weighed based on a thorough assessment of the risk-benefit ratio. Robust translational research and clinical trials are needed to determine the efficacy and safety of these interventions. Finally, harmonizing assessment protocols across centers would enhance the quality and comparability of data, facilitating future collaborative and data-sharing efforts.

Author Contributions

G. Martin-Blondel: drafting/revision of the manuscript for content, including medical writing for content; major role in the acquisition of data; study concept or design; analysis or interpretation of data. B. Agac: drafting/revision of the manuscript for content, including medical writing for content. I. Cortese: drafting/revision of the manuscript for content, including medical writing for content; major role in the acquisition of data; study concept or design; analysis or interpretation of data.

Study Funding

I. Cortese and B. Agac are supported by the NINDS Intramural Research Program, NIH.

Disclosure

The authors report no relevant disclosures. Full disclosure form information provided by the authors is available with the full text of this article at Neurology.org/cp.

Publication History

Received by *Neurology® Clinical Practice* September 17, 2025. Accepted in final form December 19, 2025. Submitted and externally peer-reviewed. The handling editor was Associate Editor John P. Ney, MD, MPH.

References

1. Cortese I, Reich DS, Nath A. Progressive multifocal leukoencephalopathy and the spectrum of JC virus-related disease. *Nat Rev Neurol.* 2021;17(1):37-51. doi:10.1038/s41582-020-00427-y
2. Berger JR, Aksamit AJ, Clifford DB, et al. PML diagnostic criteria: consensus statement from the AAN neuroinfectious disease section. *Neurology.* 2013;80(15):1430-1438. doi:10.1212/WNL.0b013e31828c2fa1
3. Joly M, Conte C, Cazanave C, et al. Progressive multifocal leukoencephalopathy: epidemiology and spectrum of predisposing conditions. *Brain.* 2023;146(1):349-358. doi:10.1093/brain/awac237
4. Mainardi I, Gerevini S, Tarantino A, et al. Changing clinical and laboratory characteristics of progressive multifocal leukoencephalopathy: a retrospective national cohort study. *Clin Infect Dis.* 2025. 9:ciaf501. doi:10.1093/cid/ciaf501
5. Melliez H, Mary-Krause M, Bocket L, et al. Risk of progressive multifocal leukoencephalopathy in the combination antiretroviral therapy era in the French hospital database on human immunodeficiency virus (ANRS-C4). *Clin Infect. Dis* 2018;67(2):275-282. doi:10.1093/cid/ciy074
6. Iacobaeus E, Burkill S, Bahmanyar S, et al. The national incidence of PML in Sweden, 1988-2013. *Neurology.* 2018;90(6):e498-e506. doi:10.1212/WNL.0000000000004926
7. Sakurai S, Maezawa M, Nakao S, et al. Progressive multifocal leukoencephalopathy analyzed using the Japanese adverse drug event report database. *J Neurol Sci.* 2023;455:122789. doi:10.1016/j.jns.2023.122789
8. Ho PR, Koendgen H, Campbell N, Haddock B, Richman S, Chang I. Risk of natalizumab-associated progressive multifocal leukoencephalopathy in patients with multiple sclerosis: a retrospective analysis of data from four clinical studies. *Lancet Neurol.* 2017;16(11):925-933. doi:10.1016/S1474-4422(17)30282-X
9. Raisch DW, Rafi JA, Chen C, Bennett CL. Detection of cases of progressive multifocal leukoencephalopathy associated with new biologicals and targeted cancer therapies from the FDA's adverse event reporting system. *Expert Opin Drug Saf.* 2016;15(8):1003-1011. doi:10.1080/14740338.2016.1198775
10. Bennett CL, Berger JR, Sartor O, et al. Progressive multi-focal leucoencephalopathy among ibrutinib-treated persons with chronic lymphocytic leukaemia. *Br J Haematol.* 2018;180(2):301-304. doi:10.1111/bjh.14322
11. Goldman A, Raschi E, Chapman J, et al. Progressive multifocal leukoencephalopathy in patients treated with chimeric antigen receptor T cells. *Blood.* 2023;141(6):673-677. doi:10.1182/blood.2022017386
12. Mackenzie S, Laurence A, O'Reilly M, Peggs KS, Roddie C. Progressive multifocal leukoencephalopathy in the era of chimeric antigen receptor T-cell therapy. *Lancet Haematol.* 2021;8(12):e870-e873. doi:10.1016/S2352-3026(21)00316-1
13. McEntire CRS, Fletcher A, Toledano M, et al. Characteristics of progressive multifocal leukoencephalopathy associated with sarcoidosis without therapeutic immune suppression. *JAMA Neurol.* 2023;80(6):624-633. doi:10.1001/jamaneurol.2023.0841
14. Lyons J, Hughes R, McCarthy K, et al. Progressive multifocal leukoencephalopathy outcomes in patients with multiple sclerosis treated with dimethyl fumarate. *Mult Scler J Exp Transl Clin.* 2022;8(4):20552173221132469. doi:10.1177/20552173221132469
15. Gheuens S, Pierone G, Peeters P, Koralnik IJ. Progressive multifocal leukoencephalopathy in individuals with minimal or occult immunosuppression. *J Neurol Neurosurg Psychiatry.* 2010;81(3):247-254. doi:10.1136/jnnp.2009.187666

Downloaded from https://www.neurology.org by Cardiff University (cfu) / Wales on 11 February 2026

Copyright © 2026 American Academy of Neurology. Unauthorized reproduction of this article is prohibited.

16. Vermersch P, Kappos L, Gold R, et al. Clinical outcomes of natalizumab-associated progressive multifocal leukoencephalopathy. *Neurology.* 2011;76(20):1697-1704. doi:10.1212/WNL.0b013e31821a446b
17. Huang D, Cossoy M, Li M, et al. Inflammatory progressive multifocal leukoencephalopathy in human immunodeficiency virus-negative patients. *Ann Neurol.* 2007;62(1):34-39. doi:10.1002/ana.21085
18. Martin-Blondel G, Delobel P, Blancher A, et al. Pathogenesis of the immune reconstitution inflammatory syndrome affecting the central nervous system in patients infected with HIV. *Brain.* 2011;134(Pt 4):928-946. doi:10.1093/brain/awq365
19. Koralnik IJ, Wuthrich C, Dang X, et al. JC virus granule cell neuronopathy: a novel clinical syndrome distinct from progressive multifocal leukoencephalopathy. *Ann Neurol.* 2005;57(4):576-580. doi:10.1002/ana.20431
20. Agnihotri SP, Wuthrich C, Dang X, et al. A fatal case of JC virus meningitis presenting with hydrocephalus in a human immunodeficiency virus-seronegative patient. *Ann Neurol.* 2014;76(1):140-147. doi:10.1002/ana.24192
21. Reoma LB, Trindade CJ, Monaco MC, et al. Fatal encephalopathy with wild-type JC virus and ruxolitinib therapy. *Ann Neurol.* 2019;86(6):878-884. doi:10.1002/ana.25608
22. Hupin N, Hoogewoud F, Sallo FB, Vermeirsch S, Suttels V, Guex-Crosier Y. Persistence of intraocular JC-virus associated with a MacTel phenotype. *AIDS.* 2025;39(9):1307-1309. doi:10.1097/QAD.0000000000004240
23. Varenne F, Siegfried-Vergnon A, Lhomme S, et al. JC virus-related retinopathy. *JAMA Ophthalmol.* 2025. 143(9):785-789. doi:10.1001/jamaophthalmol.2025.2235
24. Wijburg MT, Kleerekooper I, Lissenberg-Witte BI, et al. Association of progressive multifocal leukoencephalopathy lesion volume with JC virus polymerase chain reaction results in cerebrospinal fluid of natalizumab-treated patients with multiple sclerosis. *JAMA Neurol.* 2018;75(7):827-833. doi:10.1001/jamaneurol.2018.0094
25. Dybko J, Szlasa W, Gil L, et al. Progressive multifocal leukoencephalopathy (PML) after hematopoietic cell transplantation (HCT): a retrospective study of infectious diseases working party (IDWP) of the EBMT. *Bone Marrow Transpl.* 2025. 60(9):1265-1268. doi:10.1038/s41409-025-02635-w
26. Baldassari LE, Wattjes MP, Cortese ICM, et al. The neuroradiology of progressive multifocal leukoencephalopathy: a clinical trial perspective. *Brain.* 2022;145(2):426-440. doi:10.1093/brain/awab419
27. Cortese I, Norato G, Harrington PR, et al. Biomarkers for progressive multifocal leukoencephalopathy: emerging data for use of JC virus DNA copy number in clinical trials. *Lancet Neurol.* 2024;23(5):534-544. doi:10.1016/S1474-4422(24)00099-1
28. Khanna N, Elzi L, Mueller NJ, et al. Incidence and outcome of progressive multifocal leukoencephalopathy over 20 years of the Swiss HIV cohort study. *Clin Infect Dis.* 2009;48(10):1459-1466. doi:10.1086/598335
29. Gasnault J, Costagliola D, Hendel-Chavez H, et al. Improved survival of HIV-1-infected patients with progressive multifocal leukoencephalopathy receiving early 5-drug combination antiretroviral therapy. *PLoS One.* 2011;6:e20967. doi:10.1371/journal.pone.0020967
30. Clotet B, Feinberg J, van Lunzen J, et al. Once-daily dolutegravir versus darunavir plus ritonavir in antiretroviral-naive adults with HIV-1 infection (FLAMINGO): 48 week results from the randomised open-label phase 3b study. *Lancet.* 2014;383(9936):2222-2231. doi:10.1016/S0140-6736(14)60084-2
31. Serrano-Villar S, Martinez-Sanz J, Ron R, et al. Effects of first-line antiretroviral therapy on the CD4/CD8 ratio and CD8 cell counts in CoRIS: a prospective multicentre cohort study. *Lancet HIV.* 2020;7(8):e565-e573. doi:10.1016/S2352-3018(20)30202-2
32. Burgos J, Moreno-Fornes S, Reyes-Uruena J, et al. Mortality and immunovirological outcomes in patients with advanced HIV disease on their first antiretroviral treatment: differential impact of antiretroviral regimens. *J Antimicrob Chemother.* 2022;78(1):108-116. doi:10.1093/jac/dkac361
33. Landi D, De Rossi N, Zagaglia S, et al. No evidence of beneficial effects of plasmapheresis in natalizumab-associated PML. *Neurology.* 2017;88(12):1144-1152. doi:10.1212/WNL.0000000000003740
34. Wuthrich C, Kesari S, Kim WK, et al. Characterization of lymphocytic infiltrates in progressive multifocal leukoencephalopathy: co-localization of CD8(+) T cells with JCV-infected glial cells. *J Neurovirol.* 2006;12(2):116-128. doi:10.1080/13550280600716604
35. Muller M, Wandel S, Colebunders R, et al. Immune reconstitution inflammatory syndrome in patients starting antiretroviral therapy for HIV infection: a systematic review and meta-analysis. *Lancet Infect Dis.* 2010;10(4):251-261. doi:10.1016/S1473-3099(10)70026-8
36. French MA. HIV/AIDS: immune reconstitution inflammatory syndrome: a reappraisal. *Clin Infect Dis.* 2009;48(1):101-107. doi:10.1086/595006
37. Martin-Blondel G, Bauer J, Cuvinciuc V, et al. In situ evidence of JC virus control by CD8+ T cells in PML-IRIS during HIV infection. *Neurology.* 2013;81(11):964-970. doi:10.1212/WNL.0b013e3182a43e6d
38. Johnson T, Nath A. Neurological complications of immune reconstitution in HIV-infected populations. *Ann N Y Acad Sci.* 2010;1184:106-120. doi:10.1111/j.1749-6632.2009.05111.x
39. Adrianzen Herrera D, Ayyappan S, Jasra S, et al. Characteristics and outcomes of progressive multifocal leukoencephalopathy in hematologic malignancies and stem cell transplant–a case series. *Leuk Lymphoma.* 2019;60(2):395-401. doi:10.1080/10428194.2018.1474523
40. Dong-Si T, Gheuens S, Gangadharan A, et al. Predictors of survival and functional outcomes in natalizumab-associated progressive multifocal leukoencephalopathy. *J Neurovirol.* 2015;21(6):637-644. doi:10.1007/s13365-015-0316-4
41. Pocora MM, Bini P, Berzero G, et al. Adoptive JC virus-specific T lymphocytes for the treatment of progressive multifocal leukoencephalopathy: experience from two Italian centers. *Viruses.* 2025;17(7):934. doi:10.3390/v17070934
42. Berenguer J, Miralles P, Arrizabalaga J, et al. Clinical course and prognostic factors of progressive multifocal leukoencephalopathy in patients treated with highly active antiretroviral therapy. *Clin Infect Dis.* 2003;36(8):1047-1052. doi:10.1086/374048
43. Marzocchetti A, Tompkins T, Clifford DB, et al. Determinants of survival in progressive multifocal leukoencephalopathy. *Neurology.* 2009;73(19):1551-1558. doi:10.1212/WNL.0b013e3181c0d4a1
44. Gheuens S, Bord E, Kesari S, et al. Role of CD4+ and CD8+ T-cell responses against JC virus in the outcome of patients with progressive multifocal leukoencephalopathy (PML) and PML with immune reconstitution inflammatory syndrome. *J Virol.* 2011;85(14):7256-7263. doi:10.1128/JVI.02506-10
45. Lajaunie R, Mainardi I, Gasnault J, et al. Outcome of progressive multifocal leukoencephalopathy treated by Interleukin-7. *Ann Neurol.* 2022;91(4):496-505. doi:10.1002/ana.26307
46. Boumaza X, Bonneau B, Roos-Weil D, et al. Progressive multifocal leukoencephalopathy treated by immune checkpoint inhibitors. *Ann Neurol.* 2023;93(2):257-270. doi:10.1002/ana.26512
47. Cortese I, Muranski P, Enose-Akahata Y, et al. Pembrolizumab treatment for progressive multifocal leukoencephalopathy. *N Engl J Med.* 2019;380(17):1597-1605. doi:10.1056/NEJMoa1815039
48. Berzero G, Basso S, Stoppini L, et al. Adoptive transfer of JC virus-specific T lymphocytes for the treatment of progressive multifocal leukoencephalopathy. *Ann Neurol.* 2021;89(4):769-779. doi:10.1002/ana.26020
49. Cortese I, Beck ES, Al-Louzi O, et al. BK virus-specific T cells for immunotherapy of progressive multifocal leukoencephalopathy: an open-label, single-cohort pilot study. *Lancet Neurol.* 2021;20(8):639-652. doi:10.1016/S1474-4422(21)00174-5
50. Mohn N, Grote-Levi L, Wattjes MP, et al. Directly isolated allogeneic virus-specific T cells in progressive multifocal leukoencephalopathy. *JAMA Neurol.* 2024;81(11):1187-1198. doi:10.1001/jamaneurol.2024.3324
51. Alkhaldi H, Kharfan-Dabaja M, El Fakih R, Aljurf M. Safety and efficacy of immune checkpoint inhibitors after allogeneic hematopoietic cell transplantation. *Bone Marrow Transpl.* 2023;58(10):1075-1083. doi:10.1038/s41409-023-02073-6
52. Lopez-Olivo MA, Kachira JJ, Abdel-Wahab N, et al. A systematic review and meta-analysis of observational studies and uncontrolled trials reporting on the use of checkpoint blockers in patients with cancer and pre-existing autoimmune disease. *Eur J Cancer.* 2024;207:114148. doi:10.1016/j.ejca.2024.114148
53. Androdias G, Noroy L, Psimaras D, et al. Impact of immune checkpoint inhibitors on the course of multiple sclerosis. *Neurol Neuroimmunol Neuroinflamm.* 2024;11(2):e200202. doi:10.1212/NXI.0000000000200202
54. Murakami N, Mulvaney P, Danesh M, et al. A multi-center study on safety and efficacy of immune checkpoint inhibitors in cancer patients with kidney transplant. *Kidney Int.* 2021;100(1):196-205. doi:10.1016/j.kint.2020.12.015
55. Corey S, Smith BR, Cortese ICM. Promise and challenges of checkpoint inhibitor therapy for progressive multifocal leukoencephalopathy in HIV. *Curr HIV/AIDS Rep.* 2022;19(6):580-591. doi:10.1007/s11904-022-00626-w
56. Kim J, Kim C, Lee JA, et al. Long-term prognosis and overall mortality in patients with progressive multifocal leukoencephalopathy. *Sci Rep.* 2023;13(1):14291. doi:10.1038/s41598-023-41147-9
57. Blant JC, De Rossi NN, Gold R, et al. Presentation and outcome in S1P-RM and natalizumab-associated progressive multifocal leukoencephalopathy: a multicenter cohort study. *Neurol Neuroimmunol Neuroinflamm.* 2024;11(5):e200281. doi:10.1212/NXI.0000000000200281
58. Tan IL, McArthur JC, Clifford DB, Major EO, Nath A. Immune reconstitution inflammatory syndrome in natalizumab-associated PML. *Neurology.* 2011;77(11):1061-1067. doi:10.1212/WNL.0b013e31822e55e7
59. Tan K, Roda R, Ostrow L, McArthur J, Nath A. PML-IRIS in patients with HIV infection: clinical manifestations and treatment with steroids. *Neurology.* 2009;72(17):1458-1464. doi:10.1212/01.wnl.0000343510.08643.74
60. Antoniol C, Jilek S, Schluep M, et al. Impairment of JCV-specific T-cell response by corticotherapy: effect on PML-IRIS management? *Neurology.* 2012;79(23):2258-2264. doi:10.1212/WNL.0b013e3182768983

How to cite this article: Martin-Blondel G, Agac B, Cortese I. Practical management of progressive multifocal leukoencephalopathy and immune reconstitution inflammatory syndrome. *Neurol Clin Pract.* 2026;16(2):e200594. doi: 10.1212/CPJ.0000000000200594

Downloaded from https://www.neurology.org by Cardiff University (cfu) / Wales on 11 February 2026

Copyright © 2026 American Academy of Neurology. Unauthorized reproduction of this article is prohibited.